

proximal femur reconstruction in THR  
revision surgery  
(modular cementless revision)

Landor I.

1-st orthopaedic clinic

Charles university prague

Head: prof. MUDr. Antonin SOSNA, DrSc

## □ cemented revision

bad mechanical and biological conditions with negative consequences for osteointegration

## □ cementless revision

**monoblock** - problem with proximal fixation of the stem due to small variability, right antetorsion setting (anat. complicated cases)

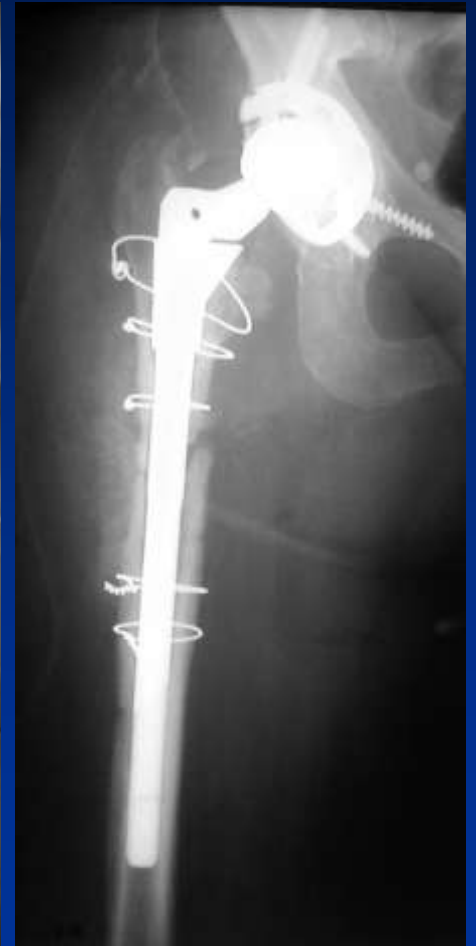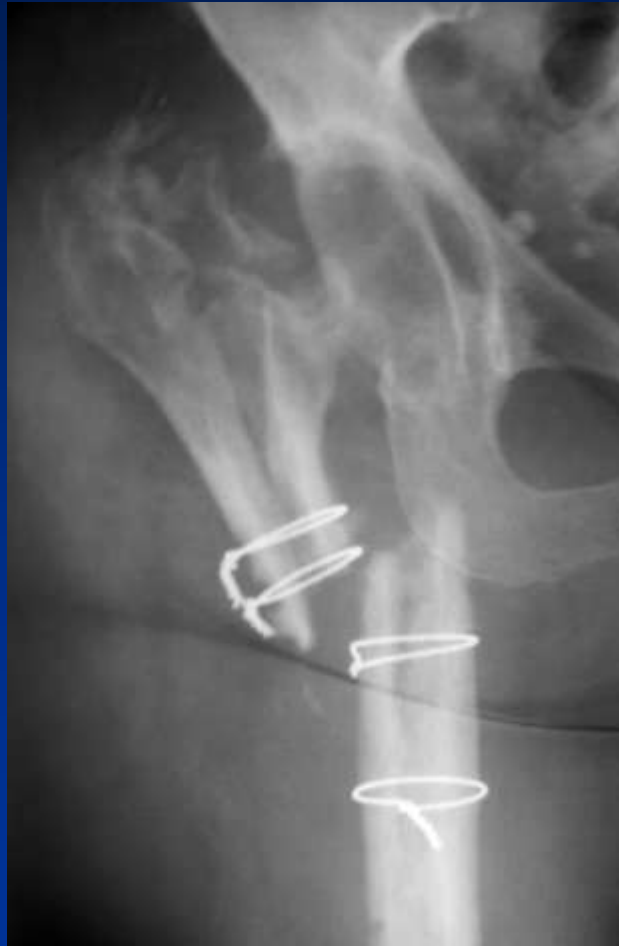**modular** – 2 groups of implants

□ preference of **rotational stability**

□ preference of **vertical stability**

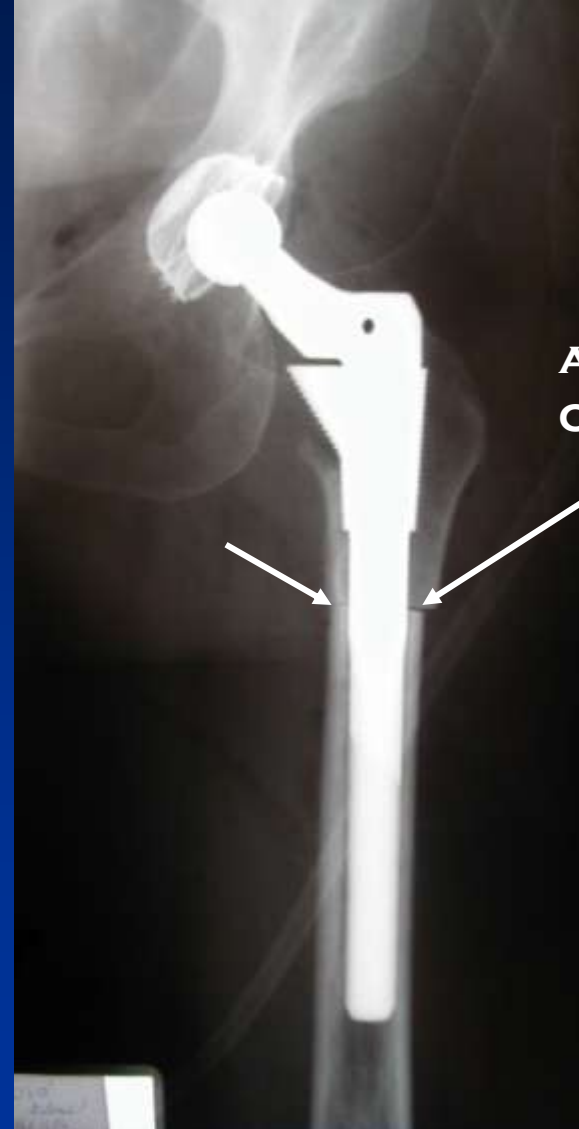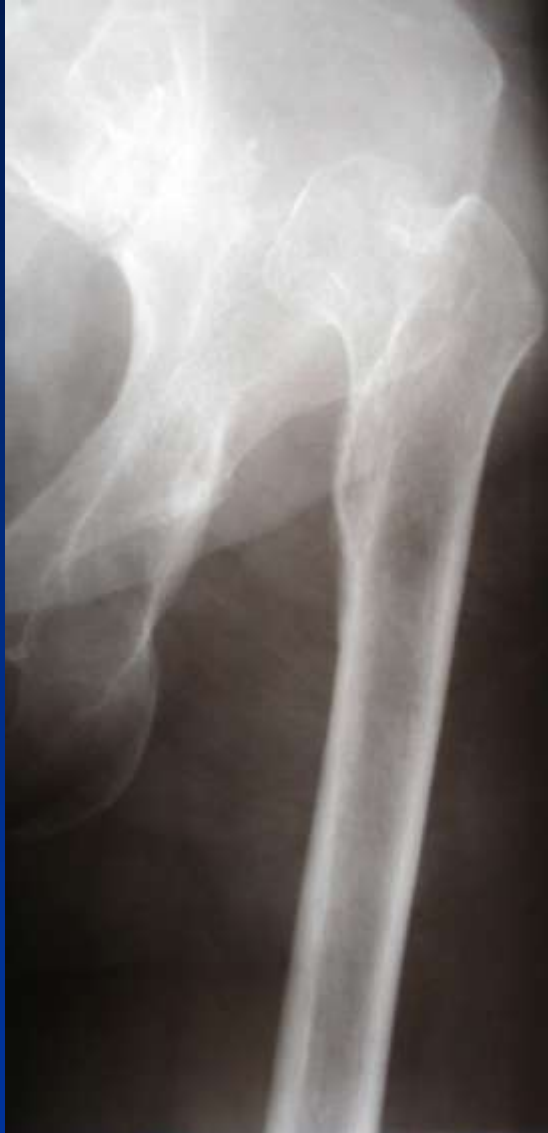# MODULAR SYSTEM WITH PREFERENCE OF ROTATIONAL STABILITY

## S ROM



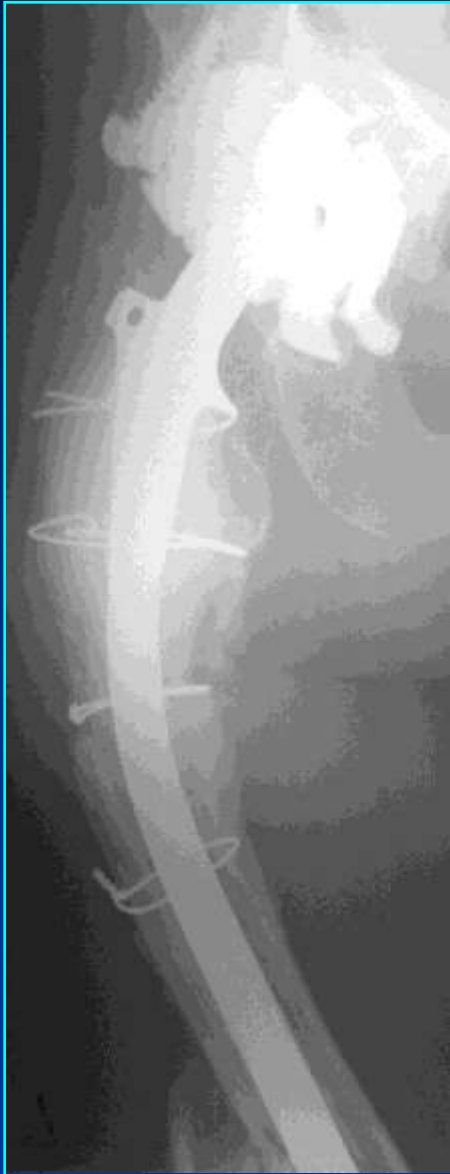CYLINDRICAL FLUTED ROD=EXTREME ROTATIONAL STABILITY

# Modular system with preference of rotational stability

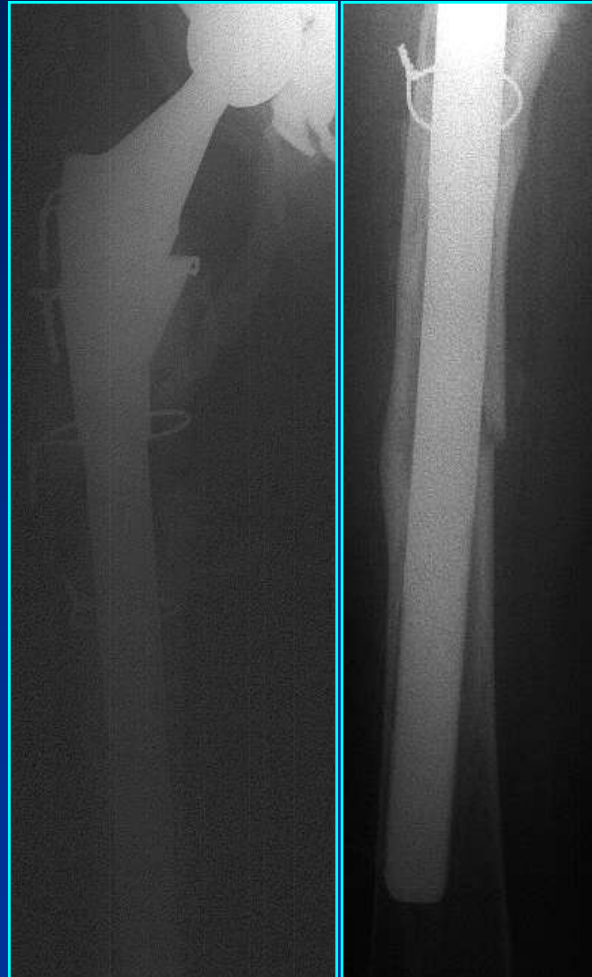

ABREV.  
OSTEOTOMY

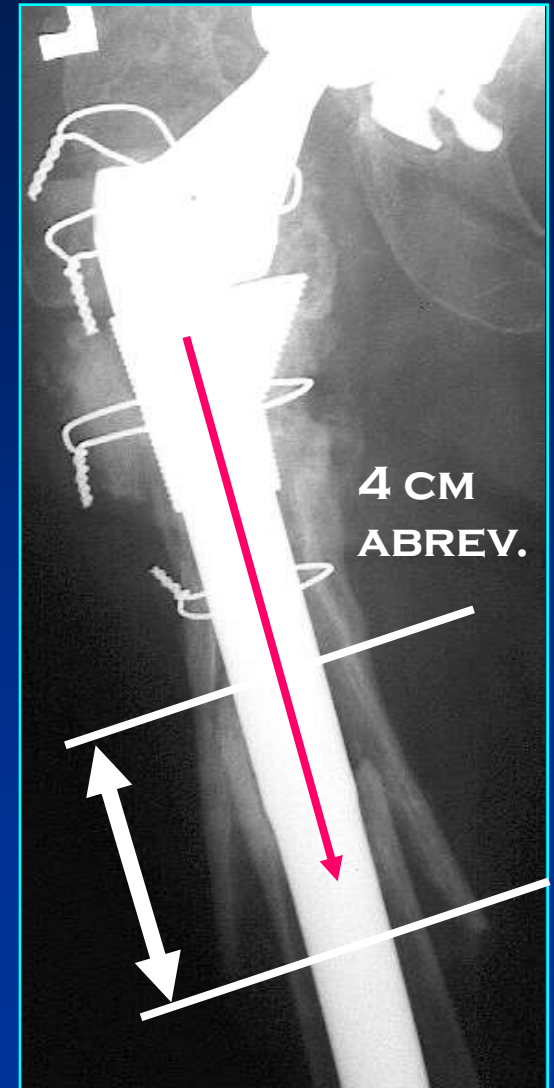
# Main S rom disadvatage – vertical instability



AFTER OPERATION



AFTER 3 WEEKS



# Revision modular stem Beznoska (2005)

- **proximal segment:**

basic (A): 6 sizes

increased lateralisation (AX): 6 sizes

- **conical fluted stem**

length available: 135, 175 a 215 mm

diameter available : 12,14,16,18, 20, 22 mm

coupling: cone


securing: screw

- **heads:**


all heads with cone 12/14



# MODULARITY: 216 COMBINATIONS



12  
VARIANTS



18  
VARIANTS



Instrument set -1st part

# Preparation of the femoral bone bed

modular system of reamers



Obr. 2a  
BEZ NÁSTAVCE:  
135 mm DŘÍK



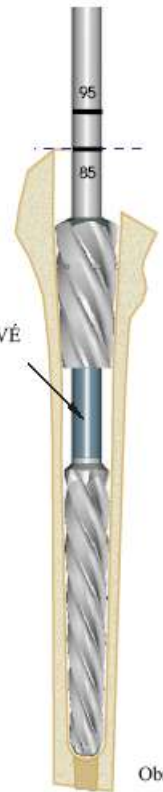
Obr. 2b  
1 NÁSTAVEC:  
175 mm DŘÍK



Obr. 2c  
2 NÁSTAVCE:  
215 mm DŘÍK



NÁSTAVEC  
STRUHADLOVÉ  
FRÉZY




Obr. 3



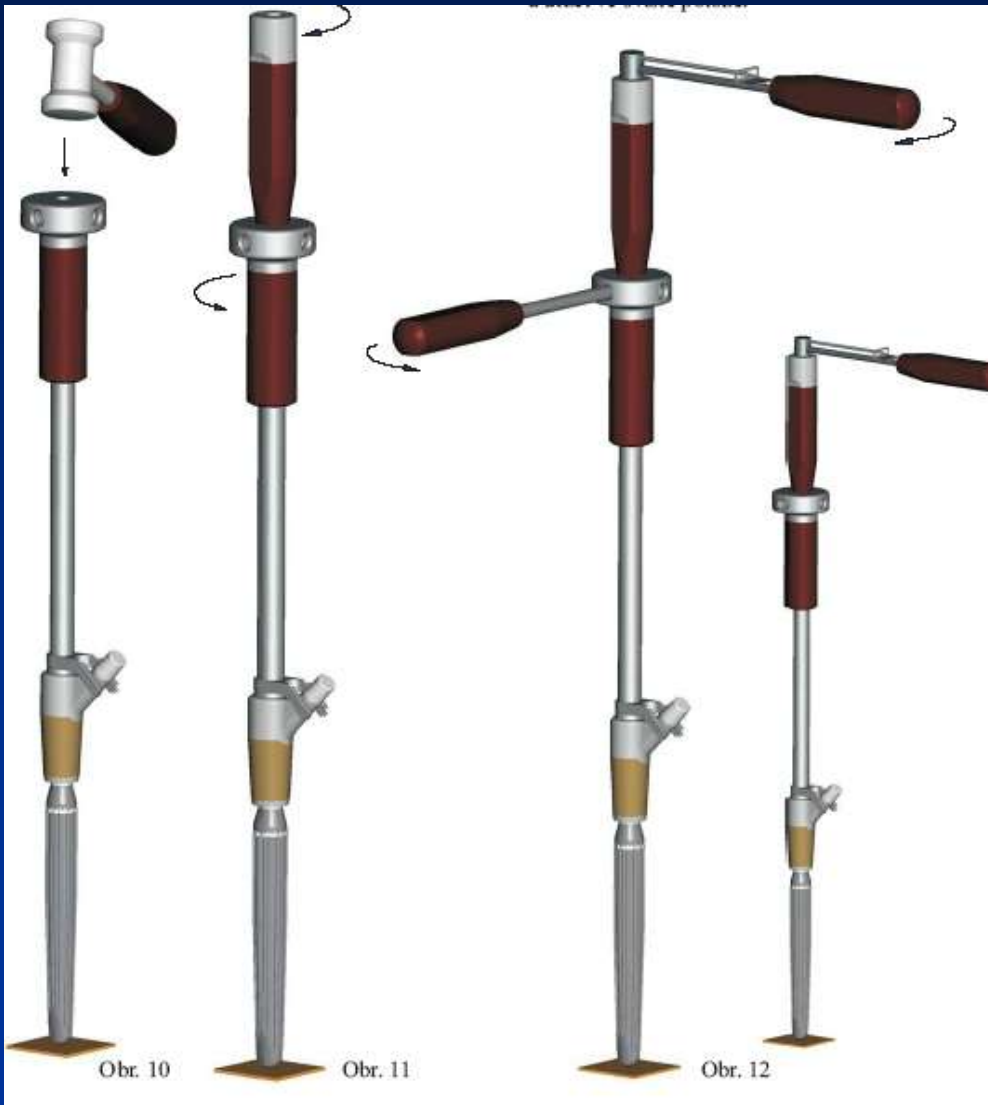## INSTRUMENT SET - 2ND PART

# COMPONENT COUPLING, INSERTION, EXTRACTION SET

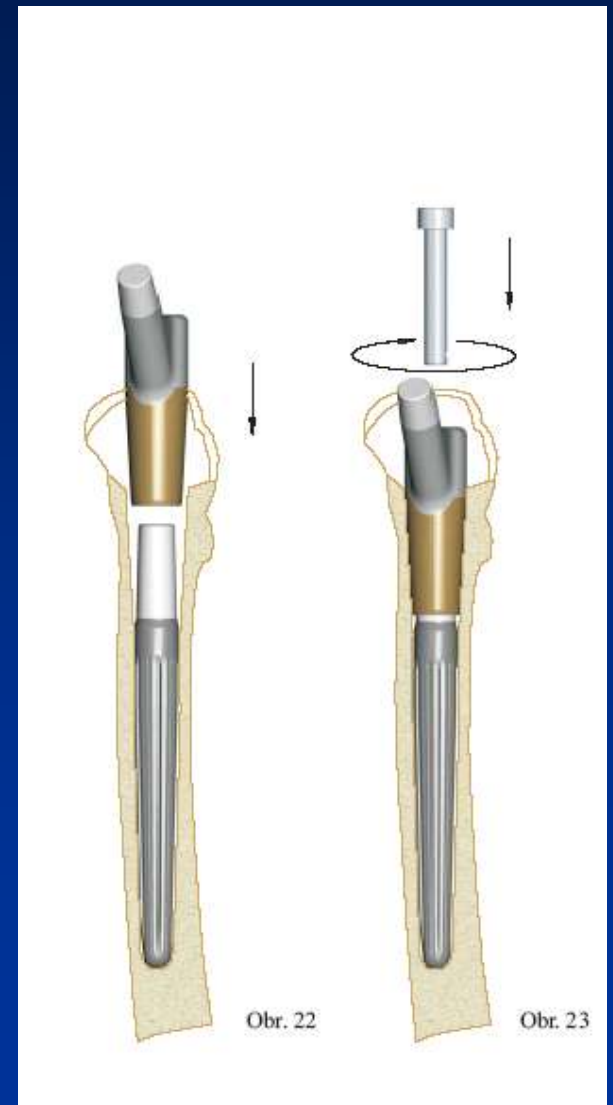


# Implant coupling and securing

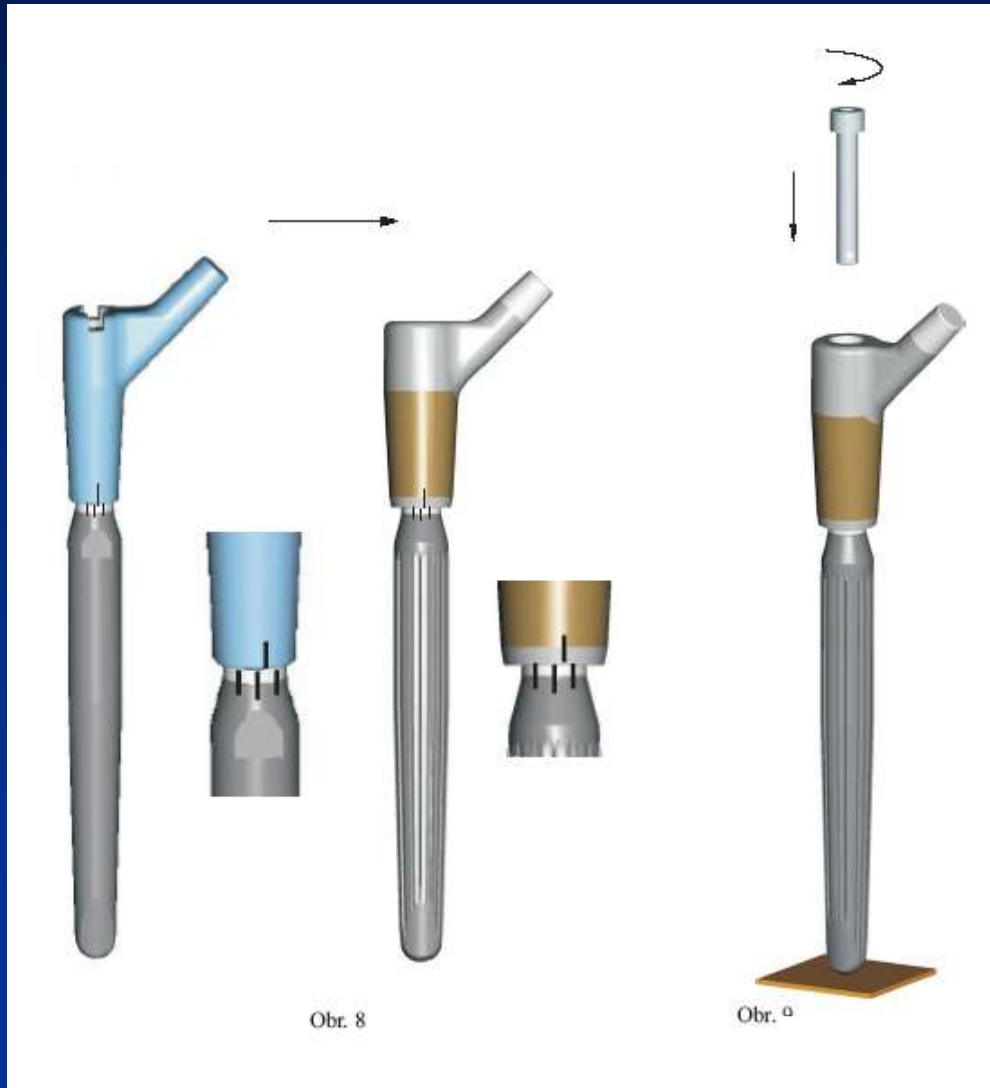
## OUTSIDE OF THE BONE BED



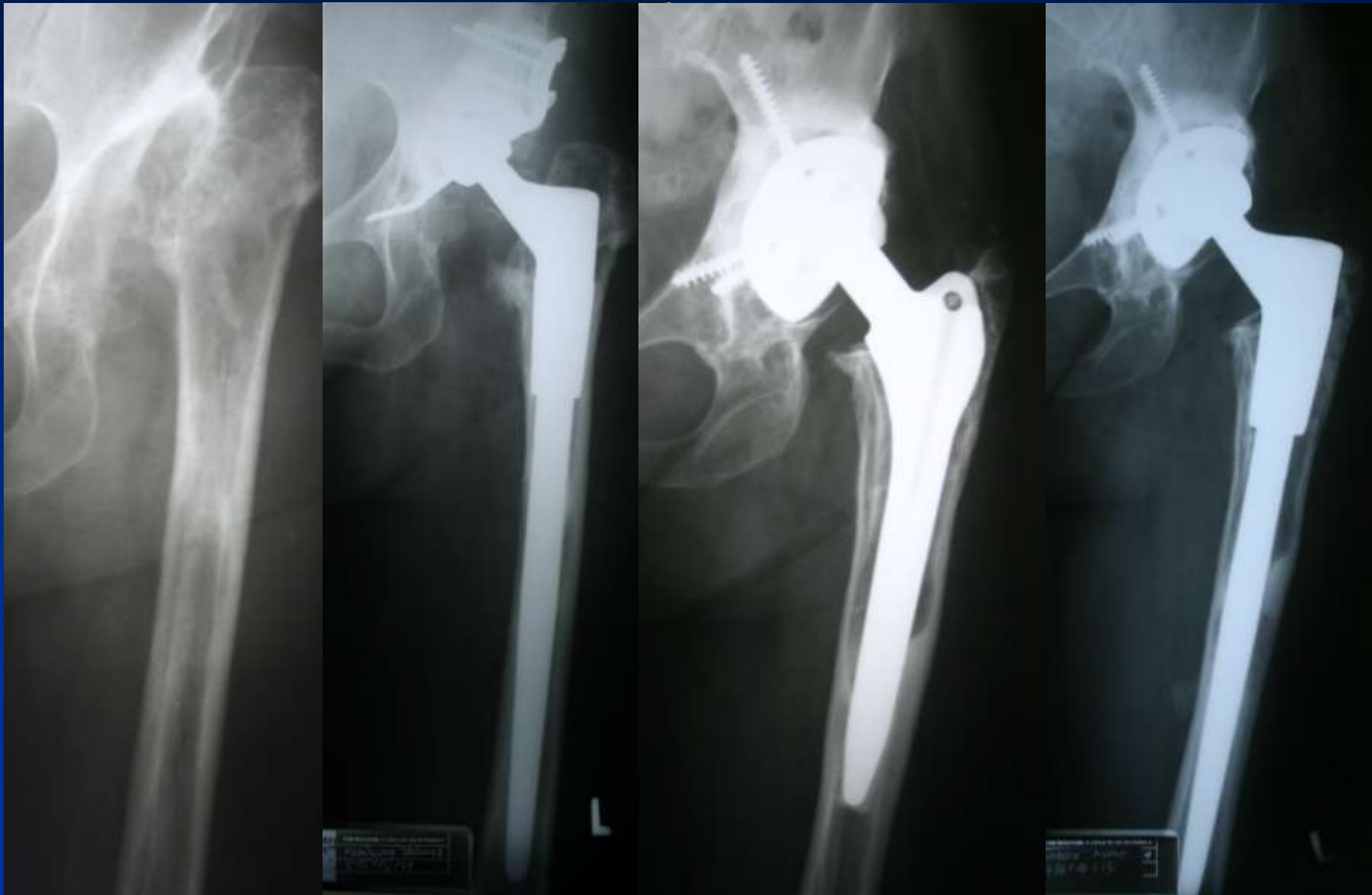## INSIDE OF THE BONE BED



# Proximal segment antetorsion setting

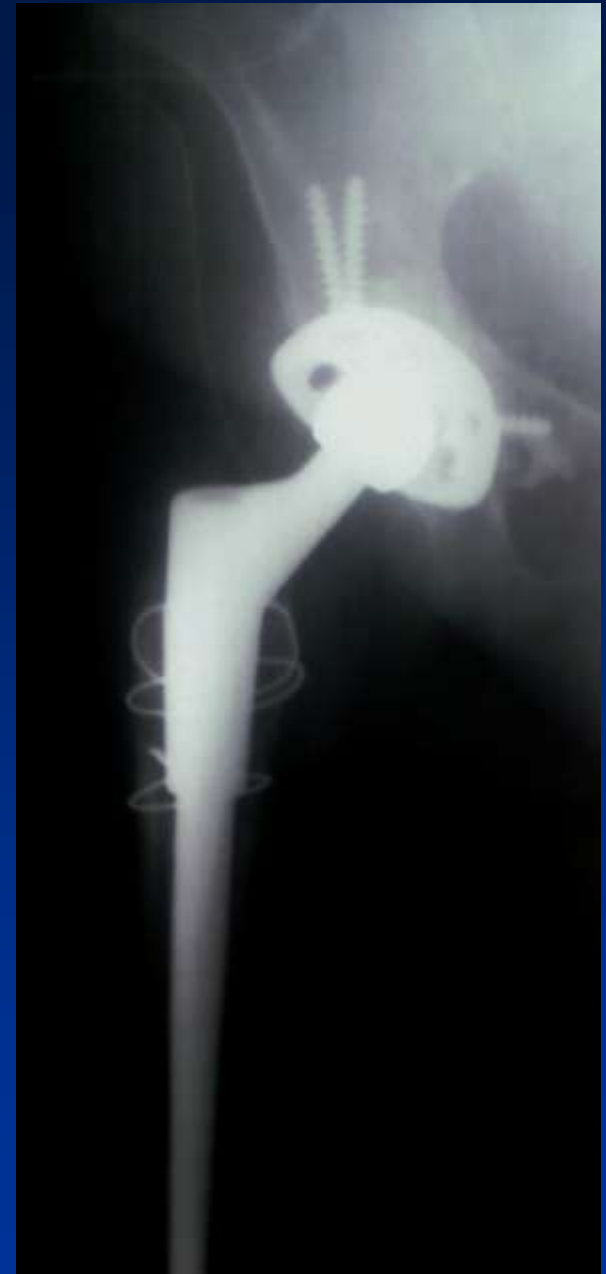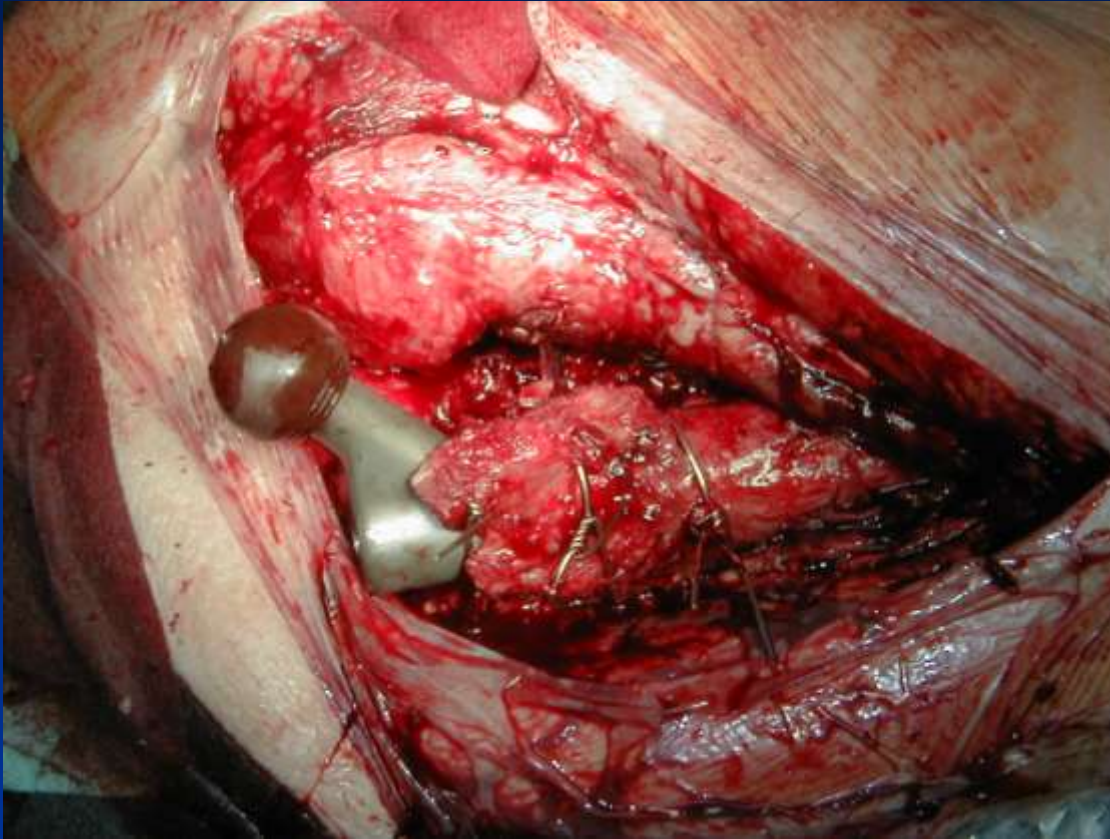


# STANDARD REVISIONS OF FEMORAL COMPONENT

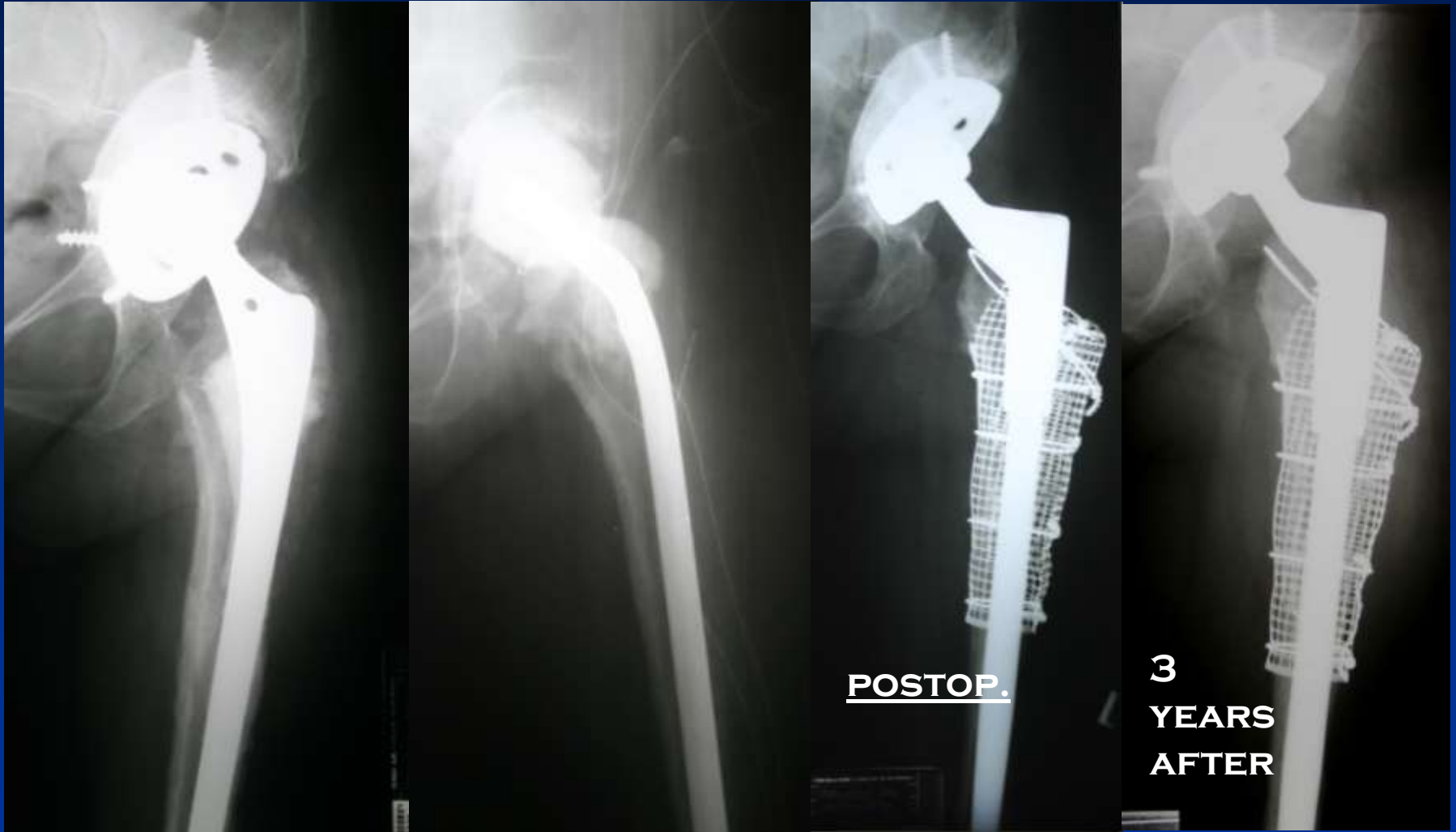



# Prox. femur reconstruction

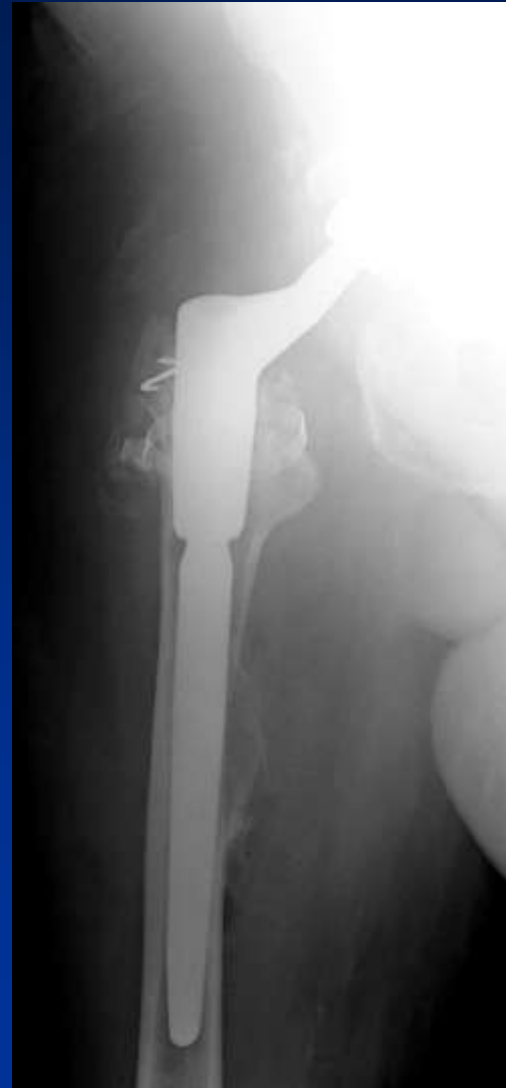
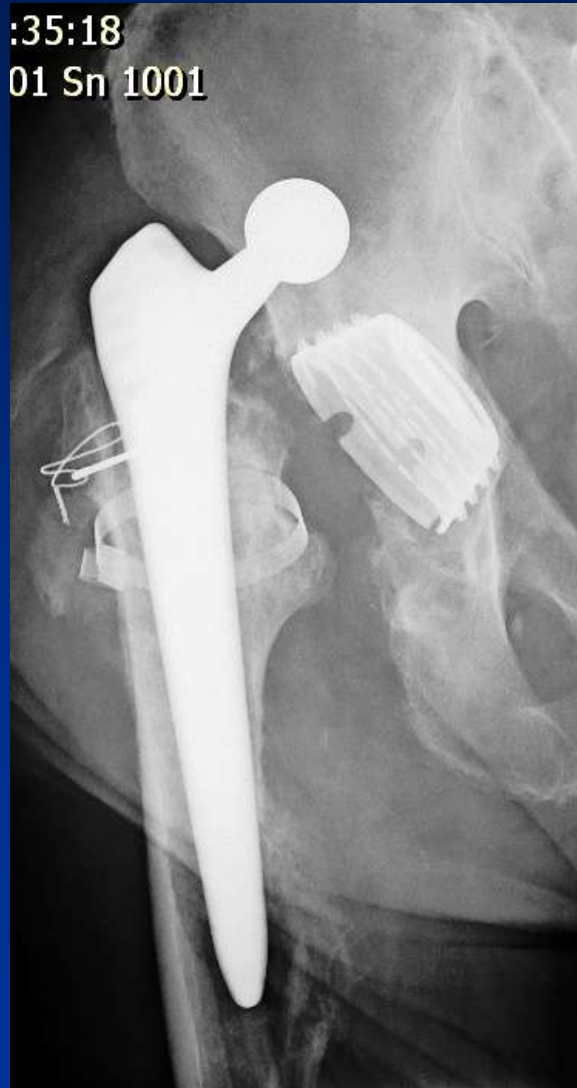
# Prox. femur reconstruction

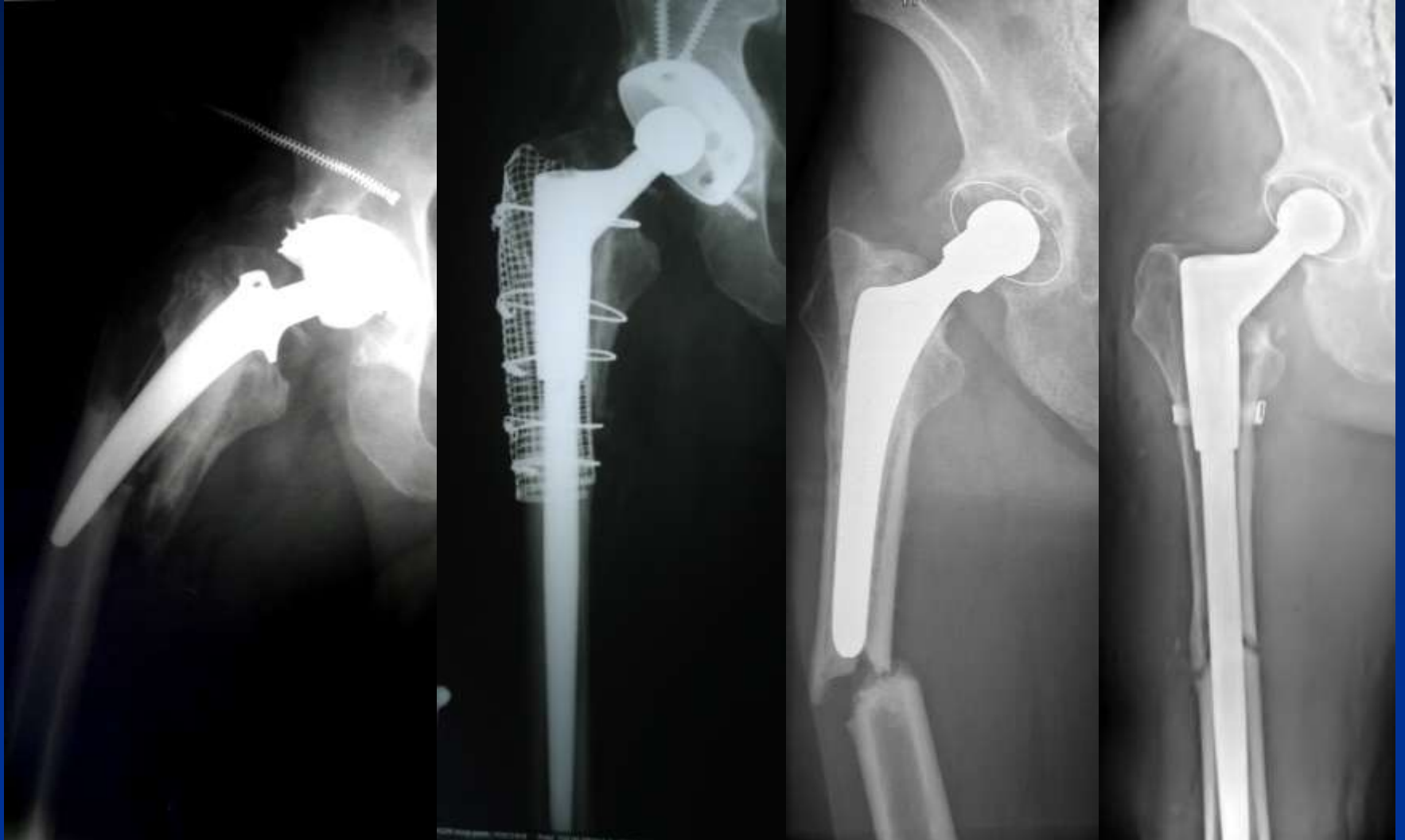



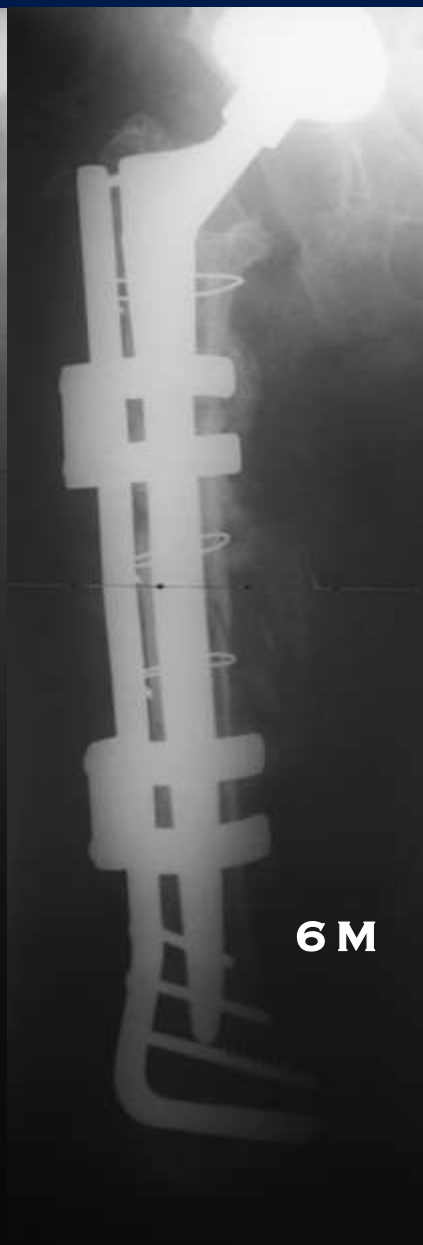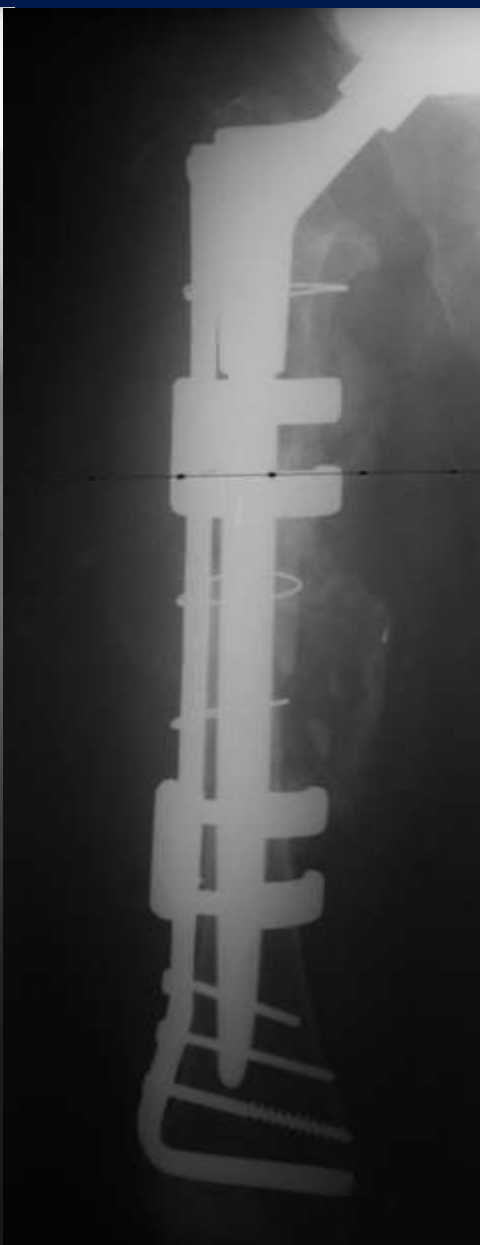
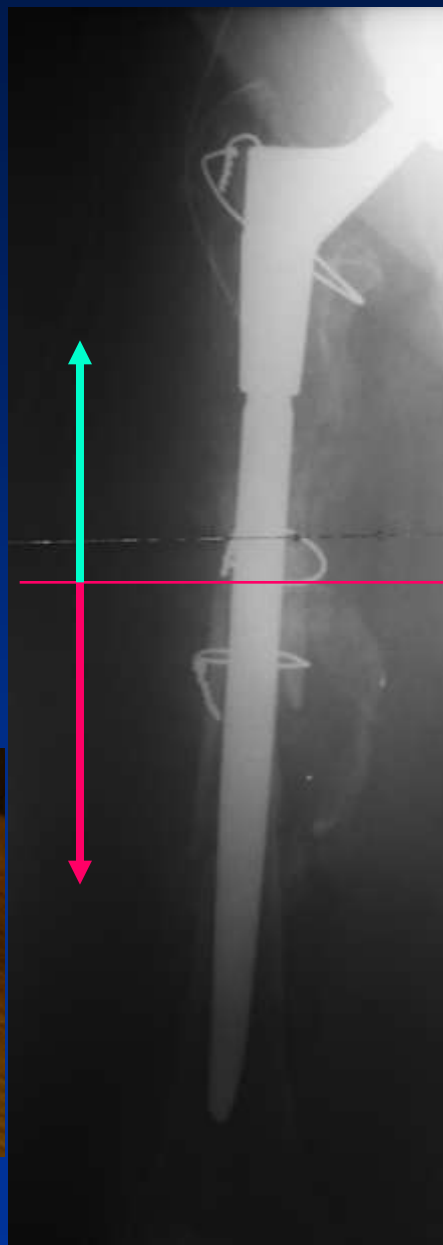
# Mistaken OP. technique



# Periprosthetic fractures



# Indication limit

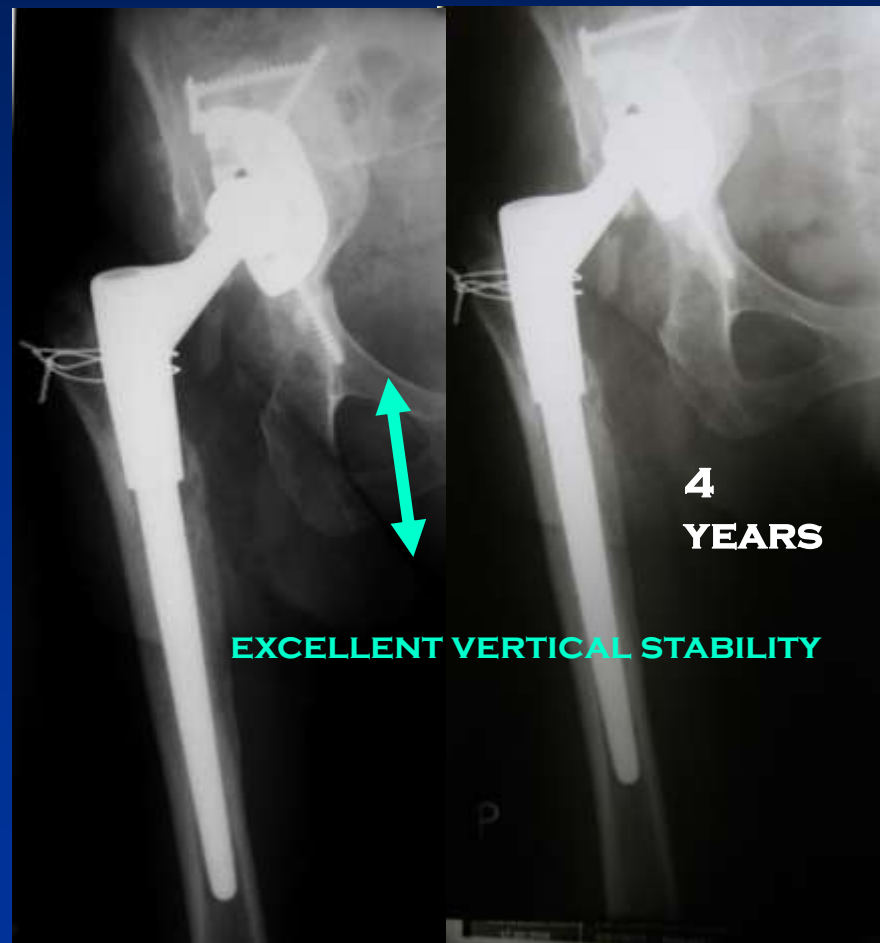


# OUR GROUP OF PATIENTS

N	MEAN FOLLOW UP	MIN.	MAX.	SD
30	2,52	0,05	4,91	1,74

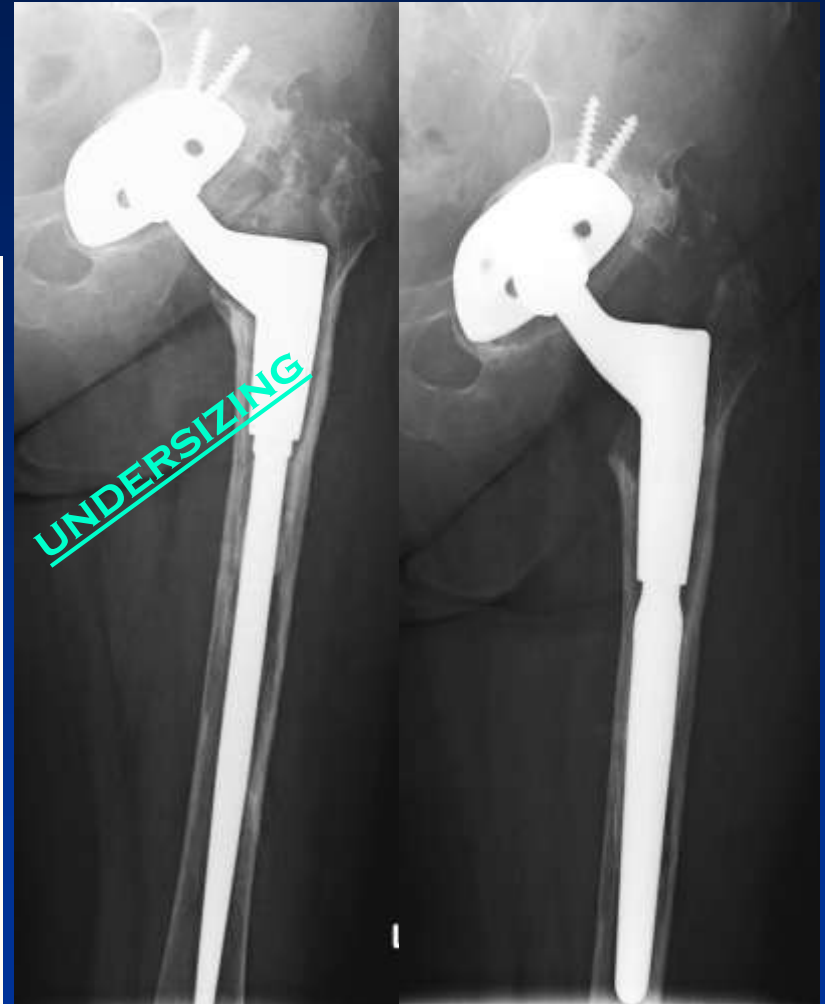
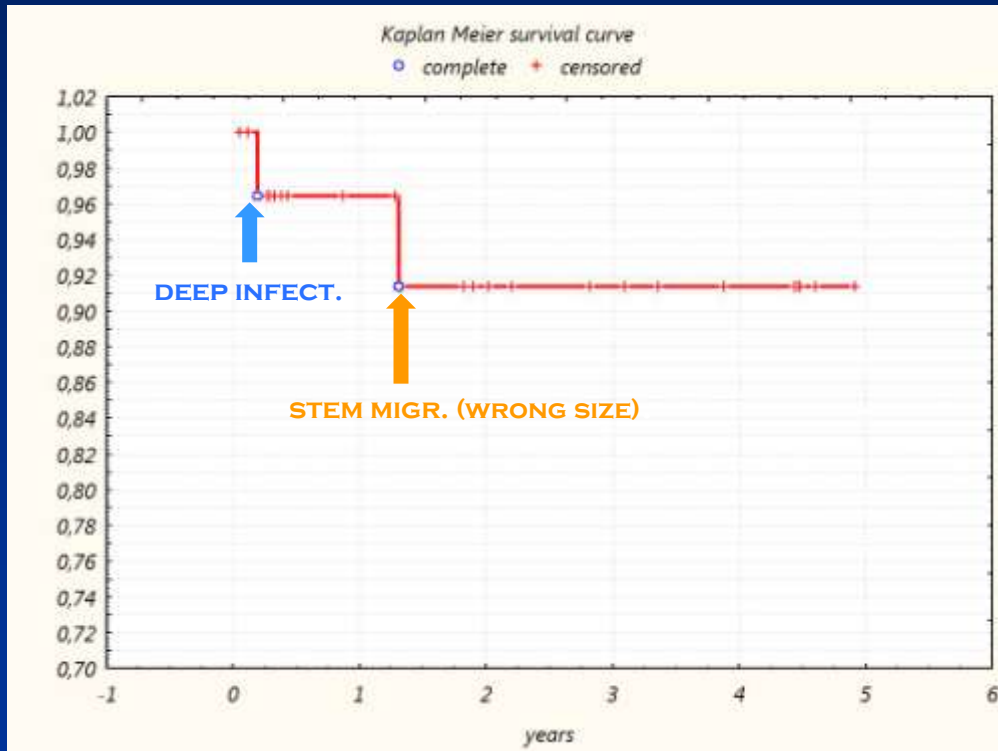
## INDICATIONS

<b>SIMPLE REVISION</b>	<b>5</b>
<b>SEGMENT FEM. DEFECT</b>	<b>17</b>
<b>PERIPROSTHETIC FRACTURE</b>	<b>8</b>



# Kaplan Meier survival curve - complications

N	MEAN FOLLOW UP
30	2,52



# Conclusion

## Revision modular stem Beznoska

- ❑ strong vertical stability
- ❑ satisfactory rotational stability
- ❑ possible to be used nearly in all cases when proximal femur reconstruction is needed.



Thank you for your attention

